

Intermittent Right Lower Quadrant Pain and a Simple Cyst

Sukhbir S. Singh, MD, FRCSC, Ramadan Elsgy, MD, Kristina Arendas, MD, Hassan Shenassa, MD, FRCSC

Department of Obstetrics and Gynecology, Ottawa General Hospital, University of Ottawa, Ottawa ON

A 43-year-old woman presented with a three-year history of intermittent right lower quadrant pain and a right simple adnexal cyst. She had presented to the emergency department on several occasions over the preceding three years because of the pain, but no intervention had been required. The cyst initially had been 4 cm in diameter and was 6 cm in diameter three years later. It was thought to be a simple para-ovarian cyst.

The patient agreed to undergo operative laparoscopy. At laparoscopy, the right fallopian tube and a simple paratubal

cyst measuring approximately 6 cm (Figure 1) were found to have undergone torsion (Figure 2). The tube was untwisted, and a normal adjacent ovary was visualized. The remaining abdominal organs, including the appendix, were normal. Right salpingectomy was performed (the patient was not interested in future fertility).

The patient was discharged later the same day. Her pain subsequently resolved completely.

Consent to publish these images has been obtained from the patient.

J Obstet Gynaecol Can 2009;31(9):797

Figure 1. Right sided paratubal cyst

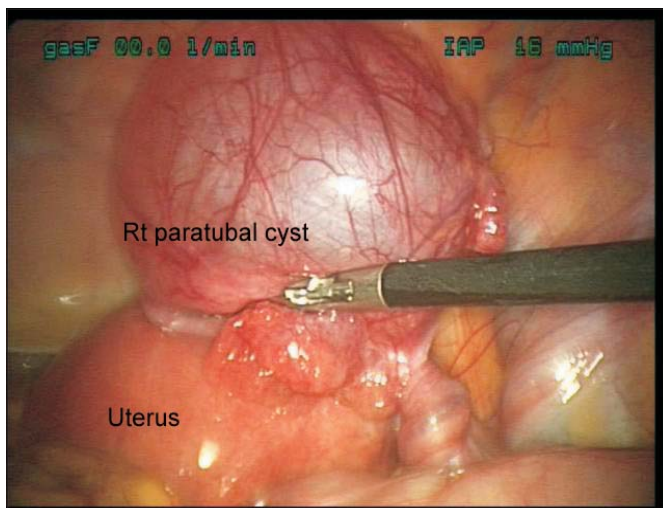


Figure 2. Torsion of right fallopian tube

