

Ultrasound Cervical Assessment in Predicting Preterm Birth

This document has been reviewed and approved by the Diagnostic Imaging Committee of the Society of Obstetricians and Gynaecologists of Canada

PRINCIPAL AUTHORS

Michiel Van den Hof, MD, FRCSC, Halifax NS
Joan Crane, MD, FRCSC, St. John's NF

DIAGNOSTIC IMAGING COMMITTEE MEMBERS

Michiel Van den Hof, (Chair) MD, FRCSC, Halifax NS
Stephen Bly PhD (Health Canada Radiation Protection Bureau), Ottawa ON
Nestor Demianczuk, MD, FRCSC, Edmonton AB (retired)
Duncan Farquharson, MD, FRCSC, Vancouver BC
Robert Gagnon, MD, FRCSC, London ON
Philip Hall, MD, FRCSC, Winnipeg MB
Barbara Lewthwaite, RN, (Woman and Child Program, St. Boniface General Hospital), Winnipeg MB
Lucie Morin, MD, FRCSC, Outremont QC
Shia Salem, MD, FRCP, Canadian Association of Radiologists Representative, Toronto ON

Abstract

Objectives: To develop national guidelines on the use of ultrasound derived cervical length in predicting preterm birth.

Options: Whether transvaginal ultrasound assessment of the cervix is superior to the digital exam and whether it is better than the transabdominal or transperineal approach.

Outcomes: Prediction of those women who deliver preterm.

Evidence: Medline search and review of bibliographies in identified articles.

Values: The evidence was reviewed by the Diagnostic Imaging Committee along with the principal authors. A quality of evidence assessment was undertaken as outlined in the report of the Canadian Task Force on the Periodic Health Examination.

Benefits, Harms, and Costs: Preterm birth is a leading cause of perinatal morbidity and mortality. Improved prediction for those women at increased risk for this complication may lead to more successful management strategies. Alternatively, the identification of those women at low risk for preterm birth avoids unnecessary and often expensive interventions.

Recommendations: There is fair (class B) evidence that transvaginal ultrasound assessment of cervical length will improve the identification of those women at increased risk of preterm birth. The high negative predictive value of this assessment will help to avoid unnecessary interventions for women found to be low risk.

OBJECTIVES

Measurement of the cervix by transvaginal ultrasound can identify women at increased risk of preterm birth. This document is a guideline for effective use of transvaginal ultrasound in assessment of such risk.

INTRODUCTION

Preterm birth is the leading cause of perinatal mortality and morbidity.¹ Despite advances in perinatal care, the incidence of preterm birth continues to rise primarily due to increased multiple pregnancies as a result of assisted reproduction.² Tocolytics prolong pregnancy minimally once preterm labour has begun and are associated with significant undesirable maternal, fetal, and neonatal consequences.³ To address the prematurity problem, identification of those at increased risk is an important objective.

Increased preterm birth risk is associated with many variables, including socioeconomic marginalization, previous preterm birth, cervical 'incompetence,' smoking, and non-medical drug use. Pregnancy complications that increase

These guidelines reflect emerging clinical and scientific advances as of the date issued and are subject to change. The information should not be construed as dictating an exclusive course of treatment or procedure to be followed. Local institutions can dictate amendments to these opinions. They should be well documented if modified at the local level. None of the contents may be reproduced in any form without prior written permission of SOGC.

likelihood of preterm birth include multiple gestation, polyhydramnios, vaginal bleeding, certain uterine anomalies, and excessive uterine contractions. Despite these important associations, maternal risk scoring fails to detect up to 70 percent of infants who are delivered spontaneously before term.⁴

Other screening strategies that have been suggested include measuring of biochemical markers of inflammation and culturing for infections.⁵

ULTRASOUND VERSUS DIGITAL CERVICAL MEASUREMENT

Digital assessment of the cervix has been commonly used to diagnose premature labour or to evaluate women perceived to be at increased risk of preterm labour. Digital assessment of cervical length is subjective, varies between examiners, and underestimates true anatomic length. Digital exams before hysterectomy underestimated cervical length by approximately 14 mm, whereas transvaginal ultrasound measured length accurately.⁶ Investigations using transvaginal ultrasound measurement as the standard confirmed that digital examination underestimates cervical length.^{7,8} This underestimation may result from an inability to digitally assess the cervix length beyond the vaginal fornices unless there is two cm or more of dilation and the entire intracervical canal is examined.

COMPARISON BETWEEN TRANSVAGINAL, TRANSABDOMINAL, AND TRANSPERINEAL ULTRASOUND CERVICAL MEASUREMENT

Ultrasound assessment of the cervix was initially transabdominal, but specific disadvantages led to a preference for the transvaginal examination.^{9,10}

- Transabdominal ultrasound requires filling the bladder to assess the cervix adequately, but this may spuriously lengthen the cervix by opposing the anterior and posterior lower uterine segments,⁹ concealing cervical shortening or funnelling. In contrast, transvaginal ultrasound is performed with the bladder empty.¹⁰
- Transabdominal resolution is hampered significantly by maternal obesity, shadowing from fetal parts, and the need for lower frequency transducers.¹⁰

Transperineal ultrasound has been performed as less invasive than the transvaginal examination but most studies have found that both approaches are acceptable to women.^{11,12} Since image resolution is better transvaginally, transperineal ultrasound should be reserved for and offered to women at increased risk of preterm birth for whom vaginal assessment is unacceptably invasive or uncomfortable.^{13,14,15}

NORMAL CERVICAL LENGTH

Cervical length is normally distributed and remains relatively constant until the third trimester.^{16,17,18} Heath found at 23 weeks a mean length of 38 mm.¹⁹ Iams found a mean length at 24 weeks of 35 mm and at 28 weeks of 34 mm.²⁰ If funnelling is present, measurement should exclude the funnel and be taken from the funnel tip to the external os.²¹

TRANSVAGINAL CERVICAL MEASUREMENT IN ASYMPTOMATIC PREGNANT WOMEN

Cervical length is inversely related to preterm birth risk in asymptomatic women.^{8,19,20,22} The largest study of this relationship²⁰ noted relative risks, compared to women above the 75th percentile, of approximately four if length was less than 30 mm (25th percentile), six if less than 26 mm (10th percentile), nine if less than 22 mm (5th percentile), and 14 if less than 13 mm (1st percentile). The positive predictive value was poor (35%). Heath and colleagues¹⁹ studied women who were not at increased risk of preterm birth and, using transvaginal ultrasound at 23 weeks, found that 1.7 percent had a cervix length less than or equal to 15 mm. These women accounted for 90 percent of deliveries at less than 28 weeks and 60 percent of deliveries at less than or equal to 32 weeks. This suggests that the positive predictive value of a short cervix (≤ 15 mm) is much greater for extreme prematurity (≤ 28 weeks). The authors have created a formula to predict the risk of spontaneous delivery at less than or equal to 32 weeks based on cervical length at 23 weeks.

Although transvaginal ultrasound screening of cervical length can predict increased risk of preterm birth,²³ there is no evidence that this information can be used to improve outcomes. Consultation and the proposed location of birth should be considered. Other management options, such as cerclage, activity restriction, tocolytics, and prophylactic steroids await appropriate evaluation by randomized trials. The significant association between cervical length and preterm birth risk may not apply to women who have undergone cervical surgery resulting in permanent shortening.

TRANSVAGINAL CERVICAL MEASUREMENT WITH SUSPECTED PRETERM LABOUR

Transvaginal ultrasound is superior to digital assessment of cervical length but has limited ability to assess texture and dilation. Of all variables assessed by digital or ultrasound examination, transvaginal cervical length measurement is the best preterm birth predictor.²³ Prediction of preterm birth by internal os funnelling has been found by some investigators^{21,23} but not others.^{24,25} Cervical length greater than three cm has a high negative predictive value for delivery less than 34 weeks.^{23,26,27} This information may help patients avoid unnecessary interventions of unproven value such as tocolysis, hospitalization, and activity

restriction. Randomized trials are needed to determine optimum management following discovery of premature cervical shortening by transvaginal ultrasound.

TRANSVAGINAL CERVICAL MEASUREMENT WITH SUSPECTED PRETERM AMNIORRHEXIS

Preterm amniorrhexis conveys an increased risk of chorioamnionitis and preterm birth.^{28,29} In such circumstances, uterine contractions causing cervical change are difficult to assess because the digital cervical examination is associated with an increased risk of infection and thus should preferably be avoided until labour is established. Transvaginal ultrasound cervical measurement allows for a safe assessment when labour is suspected.³⁰

TRANSVAGINAL CERVICAL MEASUREMENT AND MANAGEMENT (FIGURE 1)

Transvaginal cervical measurement is superior to the digital examination of the cervix in predicting preterm birth.^{23,24} Difficulty and justifiable unease in estimating length digitally through the cervical canal may be decreased at later gestation or if the cervix is dilated and effaced. Digital and transvaginal ultrasound examination may be complementary in the accurate assessment of cervical length, effacement, consistency, and dilation. For possible preterm labour with intact membranes beyond

34 weeks, management choices are unlikely to be altered by cervical measurement and decisions can be based on the digital examination. Steroid prophylaxis, tocolysis, activity restriction, and hospitalization would not normally be considered at such a gestation. Below 34 weeks gestation, transvaginal cervical measurement may be valuable in avoiding unnecessary interventions based on a high negative predictive value of a cervical length greater than three cm.^{23,26,27}

If amniorrhexis is suspected under 36 weeks gestation, transvaginal measurement may be valuable to assess cervical length and changes without adding risk of chorioamnionitis. Since amniorrhexis at or beyond 36 weeks is managed in most circumstances, as such events are dealt with at term, transvaginal ultrasound is unlikely to influence management.

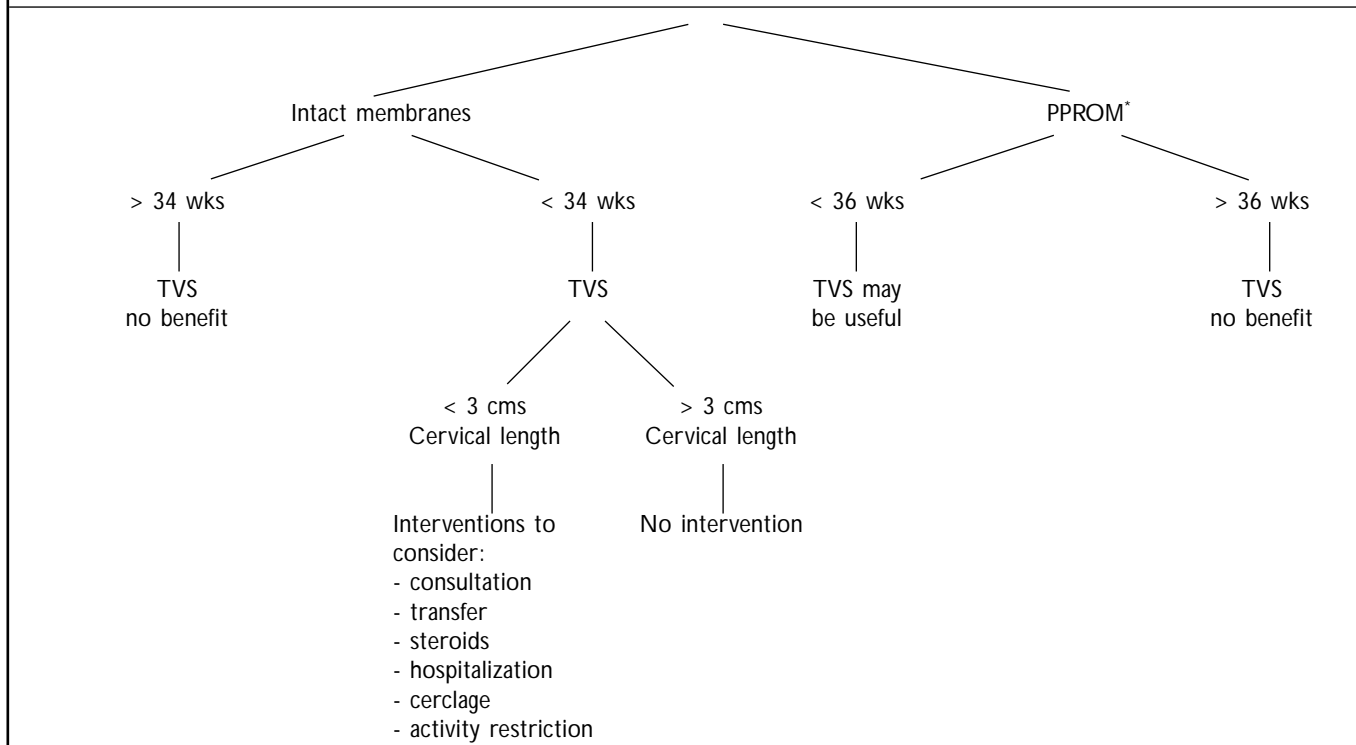
Transvaginal ultrasound cervical measurement in asymptomatic women, including those at increased risk of preterm birth, is reassuring if length after 24 weeks is greater than three cm.²⁰ Significant cervical shortening is associated with increased preterm birth risk, but as adequate randomized trials of potential interventions have not been published, no specific treatment or intervention can be endorsed.

RECOMMENDATIONS

1. Ultrasound assessment of the cervix is preferably undertaken by the transvaginal approach. (II-2 B)

FIGURE 1

TRANSVAGINAL ULTRASOUND (TVS) ASSESSMENT OF CERVICAL LENGTH



* PPROM = preterm premature rupture of membranes

2. Routine prenatal cervical length screening by transvaginal ultrasound is not supported by available evidence; however, it is indicated for women identified to be at increased risk of preterm birth. Cervical shortening is associated with increased preterm birth risk. (II-2 B)
3. Transvaginal ultrasound measurement of the cervix has a high negative predictive value if length is greater than three cm after 24 weeks. This information can be used to avoid unnecessary interventions. (II-2 B)

CONCLUSION

Transvaginal ultrasound cervical measurement is a safe and effective technique to predict increased risk of preterm delivery in selected patients. However, routine prenatal transvaginal ultrasound screening of cervical length is not supported by available evidence. Normal results can help avoid unnecessary interventions, but randomized trials are needed to determine whether interventions can improve maternal and neonatal outcomes, given cervical shortening.

J Soc Obstet Gynaecol Can 2001;23(5):418-21

REFERENCES

1. Berkowitz GS, Papienik E. Epidemiology of preterm birth. *Epidemiol Rev* 1993;15:414-3.
2. Joseph KS, Kramer MS, Wu Wen S, Alexander D. Determinants of preterm birth in Canada from 1981 through 1992, and 1992 through 1994. *N Engl J Med* 1998;339:1434-9.
3. Consensus Statement on Preterm Birth Prevention. Collaborative Conference on Preterm Birth. Ottawa, April 1998.
4. Armson BA, Dodds L. Prediction of preterm birth in a population of Canadian women. *Int J Gynecol Obstet* 1994;46(Suppl 2):93.
5. Goldenberg RL, Iams JD, Mercer BM, Meis PJ, Moawad AH, Cooper RL, et al. The Preterm Prediction Study: The value of new vs standard risk factors in predicting early and all spontaneous preterm births. NICHD MFMU Network. *Am J Public Health* 1998;88(2):233-8.
6. Jackson GM, Ludnir J, Bader TF. The accuracy of digital examination and ultrasound in the evaluation of cervical length. *Obstet Gynecol* 1992; 72:214-8.
7. Sonek JD, Iams JD, Blumenfeld M, Johnson F, Landon M, Gabbe S. Measurement of cervical length in pregnancy. Comparison between vaginal ultrasonography and digital examination. *Obstet Gynecol* 1990;76:172-5.
8. Anderson HF, Nugent CE, Wanty SB, Hayashi RH. Prediction of risk for preterm delivery by ultrasonographic measurement of cervical length. *Am J Obstet Gynecol* 1990;163:859-67.
9. Anderson HF. Transvaginal and transabdominal ultrasonography of the uterine cervix during pregnancy. *J Clin Ultrasound* 1991;19:77-83.
10. To MS, Skentou C, Cicero S, Nicolaidis KH. Cervical assessment at the routine 23 weeks' scan: problems with transabdominal sonography. *Ultrasound Obstet Gynecol* 2000;15(4):292-6.
11. Rosati P, Guariglia L. Acceptability of early transvaginal or abdominal sonography in the first half of pregnancy. *Arch Gynecol Obstet* 2000; 264(2):80-3.
12. Braithwaite JM, Economides DL. Acceptability of patients of transvaginal sonography in the elective assessment of the first trimester fetus. *Ultrasound Obstet Gynecol* 1997;9(2):76-9.
13. Kurtzman JT, Goldsmith LJ, Gall SA, Spinnato JA. Transvaginal versus transperineal ultrasonography: a blinded comparison in the assessment of cervical length at mid gestation. *Am J Obstet Gynecol* 1998; 179(4):852-7.
14. Owen J, Neely C, Northen A. Transperineal versus endovaginal ultrasonographic examination of the cervix in the mid-trimester: a blinded comparison. *Am J Obstet Gynecol* 1999;181:780-3.
15. Carr DB, Smith K, Parsons L, Chansky K, Shields LE. Ultrasonography for cervical length measurements: agreement between transvaginal and translabial techniques. *Obstet Gynecol* 2000; 96(4):554-8.
16. Cook CM, Ellwood DA. A longitudinal study of the cervix in pregnancy using transvaginal ultrasound. *Br J Obstet Gynaecol* 1996;103(1):16-8.
17. Tongsang T, Kamprapanth P, Pitaksakorn J. Cervical length in normal pregnancy as measured by transvaginal sonography. *Int J Gynecol Obstet* 1997; 58(3):313-5.
18. Smith CV, Anderson JC, Matamoras A, Rayburn WF. Transvaginal sonography of cervical width and length during pregnancy. *J Ultrasound Med* 1992;11(9):465-7.
19. Heath VC, Southall TR, Souka AP, Elisseou A, Nicolaidis KH. Cervical length at 23 weeks of gestation: prediction of spontaneous preterm delivery. *Ultrasound Obstet Gynecol* 1998;12:312-7.
20. Iams JD, Goldenberg RL, Meis PJ, Mercer BM, Moawad A, Das A, et al. The length of the cervix and the risk of spontaneous premature delivery. *N Engl J Med* 1996;334:567-72.
21. Berghella V, Kuhlman K, Weina S, Texeira L, Wapner RJ. Cervical funneling: sonographic criteria predictive of preterm delivery. *Ultrasound Obstet Gynecol* 1997;10(3):161-6.
22. Tong Sang T, Kamprapanth P, Srisomboon J, Wanapirak C, Piyamongkol W, Sirichotiyakul S. Single transvaginal sonographic measurement of cervical length early in the third trimester as a predictor of preterm delivery. *Obstet Gynecol* 1995;86:184-7.
23. Crane JM, Van den Hof MC, Armson BA, Liston R. Transvaginal ultrasound in the prediction of preterm delivery: singleton and twin gestations. *Obstet Gynecol* 1997;90:357-63.
24. Gomez R, Galasso M, Romero R, Mazor M, Sorokin Y, Gonsalves L, et al. Ultrasonographic examination of the uterine cervix is better than cervical digital examination as a predictor of the likelihood of premature delivery in patients with preterm labour and intact membranes. *Am J Obstet Gynecol* 1994;171:956-64.
25. Timor-Tritsch IE, Boozarjomehri F, Masakowski Y, Monteagudo A, Chao CR. Can a "snapshot" sagittal view of the cervix by transvaginal ultrasound predict active preterm labour? *Am J Obstet Gynecol* 1996; 174:990-5.
26. Murakawa H, Utumi T, Hasegawa I, Tanaka K, Fuzimari R. Evaluation of threatened preterm delivery by transvaginal ultrasonographic measurement of cervical length. *Obstet Gynecol* 1993;82:829-32.
27. Iams JD, Paraskos J, Landon MB, Teteris JN, Johnson FF. Cervical sonography in preterm labour. *Obstet Gynecol* 1994;84:40-6.
28. Naeye RG, Peter EC. Causes and consequences of premature rupture of fetal membranes. *Lancet* 1980; 1(8161):192-4.
29. Carroll SG, Ville Y, Greenough A, Gamsu H, Patel B, Philpott-Howard J, et al. Preterm labour amniorrhexis: intrauterine infection and interval between membrane rupture and delivery. *Arch Dis Child Fetal Neonatal Ed* 1995;72(11):F43-6.
30. Rizzo G, Capponi A, Angelini E, Vlachopoulou A, Grassi C, Romanini C. The value of transvaginal ultrasonographic examination of the uterine cervix in predicting preterm delivery in patients with preterm premature rupture of membranes. *Ultrasound Obstet Gynecol* 1998;11:23-9.